

# Superior gluteal artery perforator flap salvaged via hyperbaric oxygen therapy

Sean K Park ,<sup>1,2</sup> Kyle J Schank,<sup>1,2</sup> Abigail Engwall-Gill ,<sup>1,2</sup> James H W Clarkson<sup>1,2</sup>

<sup>1</sup>Department of Surgery, Michigan State University, East Lansing, Michigan, USA  
<sup>2</sup>Department of Surgery, Sparrow Health System, Lansing, Michigan, USA

## Correspondence to

Dr Sean K Park;  
parksean@msu.edu

Accepted 16 March 2022

## SUMMARY

The superior gluteal artery perforator (SGAP) flap can be challenging and in common with all flaps can develop venous and arterial insufficiency. Several prior studies have demonstrated the successful utility of hyperbaric oxygen therapy (HBOT) in the salvage of compromised flaps, mainly with deep inferior epigastric perforator, latissimus dorsi or transverse rectus abdominis myocutaneous flaps. SGAP flaps are autologous alternatives to abdominal-based flaps and provides adequate adipose tissue for breast reconstruction. We report a case of a woman in her 50s who underwent a delayed bilateral breast reconstruction using SGAP free flaps. Postoperatively, venous congestion of her right breast flap was noted for which she was referred for HBOT. An acceptable aesthetic result was achieved following 17 HBOT treatments. This is the first case we can find in the published literature of ischaemic SGAP free flap being salvaged by HBOT.

## BACKGROUND

Skin flap ischaemia following breast reconstruction can result in revision or reconstructive loss.<sup>1</sup> The compromise of the transferred tissue can be due to different mechanisms which include: radiation damage, low wound bed oxygen tension, vascular insufficiency, random-pattern flap ischaemia and ischaemia-reperfusion injury.<sup>2</sup> There are numerous studies that have shown efficacy of hyperbaric oxygen therapy (HBOT) as a treatment of a compromised flap. HBOT is where a patient breathes 100% oxygen in a pressurised chamber to above 1 atmosphere in an airtight chamber. Indications of HBOT include, but not limited to, thermal burn, radiation injury, carbon monoxide poisoning and compromised grafts/flaps.<sup>3</sup> A few cases of flaps salvaged by HBOT have been reported such as in deep inferior epigastric perforator, latissimus dorsi, or transverse rectus abdominis myocutaneous flaps. The superior gluteal artery perforator (SGAP) flap is an autologous alternative to abdominal-based flaps while providing enough adipose tissue for breast reconstruction.<sup>4</sup> Yaghoubian *et al* added that SGAP flap patients have less discomfort, risk of abdominal weakening, and awareness of donor scar which should prompt a surgeon to consider SGAP flap as first reconstruction option, not simply as an alternate.<sup>5</sup> There is a risk as with other flaps of sacrificing too many perforators, which can result in arteriovenous insufficiency.<sup>6</sup> We present a case where venous insufficiency was noted in a patient who received delayed bilateral breast reconstruction using SGAP free flaps. This is the first case in

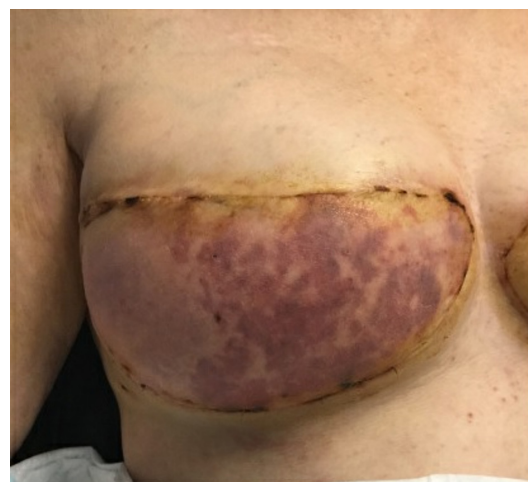the published literature of ischaemic SGAP free flap being salvaged by HBOT.

## CASE PRESENTATION

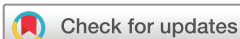A woman in her 50s with a medical history of hypothyroidism, osteopenia and depression underwent a left breast lumpectomy in 2001 for infiltrating ductal carcinoma, with subsequent adjuvant chemotherapy and radiation. She was found to be BRCA-1 positive and underwent elective total abdominal hysterectomy with bilateral salpingo-oophorectomy in 2009. She declined bilateral mastectomies. Five years later, while undergoing close surveillance, she was found to have a suspicious lesion in the right breast, which was confirmed to be infiltrating ductal carcinoma, grade 3, negative for estrogen, progesterone and HER2 receptors. Patient underwent bilateral mastectomies with right sentinel lymph node biopsy in 2014. Six years after her surgery, patient elected to undergo bilateral breast reconstruction with bilateral SGAP free flaps. At her first postoperative visit, she was noted to have venous congestion on her right sided flap and was referred to the wound clinic. She was noted to have patchy duskiness to her right breast (figure 1). The patient was deemed an acceptable candidate for HBOT to salvage the flap.

## TREATMENT

Patient subsequently underwent a HBOT regime of five times per week ranging from 2.0 atmospheres

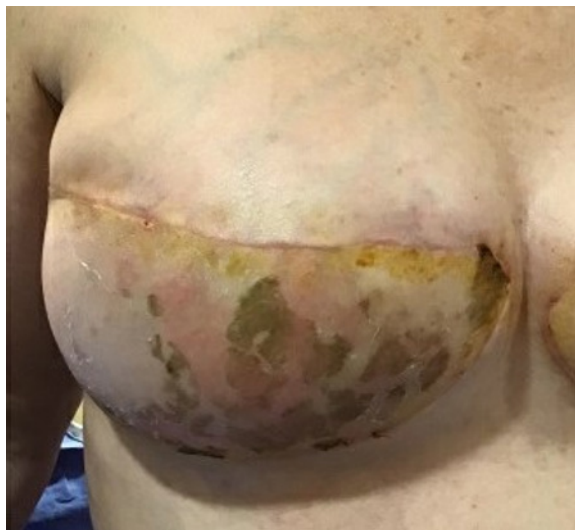

**Figure 1** Postoperative day 12 of superior gluteal artery perforator flap reconstruction presenting for her hyperbaric oxygen therapy treatment. The figure demonstrates significant ecchymosis concerning for compromise of the flap.



© BMJ Publishing Group Limited 2022. No commercial re-use. See rights and permissions. Published by BMJ.

**To cite:** Park SK, Schank KJ, Engwall-Gill A, *et al*. *BMJ Case Rep* 2022;**15**:e248411. doi:10.1136/bcr-2021-248411



**Figure 2** Following 10 hyperbaric oxygen therapy treatments of compromised superior gluteal artery perforator flap with improved echymosis.

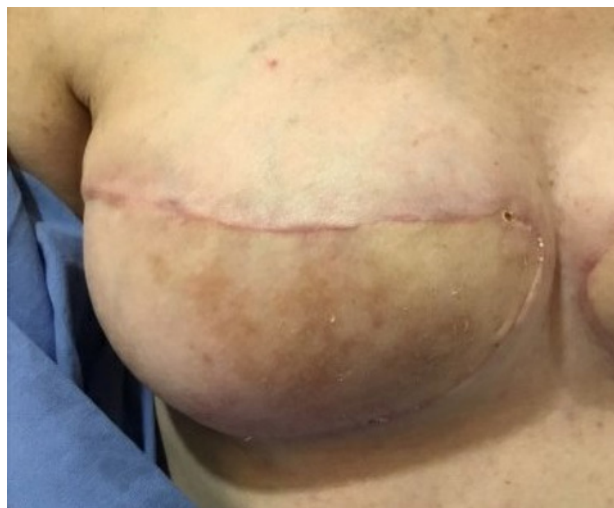
over 90 min with no breaks to 2.5 atmospheres over 90 min with two 10 min breaks allowed. The patient underwent a total of 29 HBOT sessions without complications.

### OUTCOME AND FOLLOW-UP

After just 10 HBOT treatments, the compromised flap showed significant improvements (figure 2). The flap continued to improve as demonstrated in figure 3 after 17 treatments. On completion of 29 treatments, the patient was informed to follow-up if any concerns arise. No problem has been reported. She was seen by her primary care physician 3 months from her last treatment. There was no issue with flap healing or complication from HBOT noted.

### DISCUSSION

This case of a congested SGAP flap salvaged by HBOT following breast reconstruction demonstrates HBOT as an effective salvage



**Figure 3** Complete preservation of compromised superior gluteal artery perforator flap following 17 hyperbaric oxygen therapy treatments.

### Learning points

- ▶ Hyperbaric oxygen therapy (HBOT) is non-invasive and effective treatment option to salvage compromised flaps.
- ▶ Superior gluteal artery perforator (SGAP) flap is autologous alternative to abdominal-based flaps.
- ▶ SGAP flap has become more popular as reconstructive option due to less associated comorbidity, such as abdominal weakening and discomfort.
- ▶ Flaps involved in reconstruction are prone to arteriovenous insufficiency and by using HBOT, the costs, morbidity and need for surgical procedures can be avoided for patients.

technique. SGAP flap, once commonly used as an alternative for unfeasible abdominal-based flaps, now becoming more used as first option due to higher patient satisfaction and less associated comorbidity.<sup>5</sup> However, like any other flaps, it can be prone to arteriovenous insufficiency. It is important to promptly diagnose free flap compromise using clinical judgement and correct any reversible mechanical causes.<sup>7</sup> By using HBOT effectively to salvage compromised flaps, the costs, donor site morbidity and need for multiple surgical procedures can potentially be avoided.<sup>8</sup> This case uniquely highlights compromised SGAP flap salvaged by HBOT.

**Acknowledgements** We thank Ms. Pamela Hann (MSU Department of Surgery Research Coordinator) for her assistance in obtaining the consent from the patient.

**Contributors** SKP: initiated writing and putting the data together, acquired figures and wrote the majority of the manuscript. KJS: assisted in planning for study, contributed to presentation section of the manuscript. AE-G: assisted in editing the manuscript and acquisition of data. JHWC: assisted in conception and design of the case report, assisted in editing the manuscript, was involved in the care of the patient presented.

**Funding** The authors have not declared a specific grant for this research from any funding agency in the public, commercial or not-for-profit sectors.

**Competing interests** None declared.

**Patient consent for publication** Consent obtained directly from patient(s)

**Provenance and peer review** Not commissioned; externally peer reviewed.

Case reports provide a valuable learning resource for the scientific community and can indicate areas of interest for future research. They should not be used in isolation to guide treatment choices or public health policy.

### ORCID iDs

Sean K Park <http://orcid.org/0000-0002-3785-4785>

Abigail Engwall-Gill <http://orcid.org/0000-0001-6915-7450>

### REFERENCES

- 1 Borab Z, Mirmanesh MD, Gantz M, *et al*. Systematic review of hyperbaric oxygen therapy for the treatment of radiation-induced skin necrosis. *J Plast Reconstr Aesthet Surg* 2017;70:529–38.
- 2 Francis A, Baynosa RC. Hyperbaric oxygen therapy for the compromised graft or flap. *Adv Wound Care* 2017;6:23–32.
- 3 HBO Indications - Undersea & Hyperbaric Medical Society. Available: <https://www.uhms.org/resources/hbo-indications.html> [Accessed 21 Jul 2021].
- 4 Chung K. *Grabb and Smith's plastic surgery: Eighth edition*. Wolters Kluwer Health Adis (ESP), 2019: 601–5.
- 5 Yaghoobian A, Boyd JB, Brian MD. The SGAP flap in breast reconstruction: backup or first choice? *Plast Reconstr Surg* 2011;128:29e–31.
- 6 Wongriratanachai P, Martin AM, Chaiyasate K. DIEP flap salvage by cannula venesection of the superficial inferior epigastric vein. *Eur J Plast Surg* 2016;39:151–4.
- 7 Ochoa O, Pisano S, Chrysopoulos M, *et al*. Salvage of intraoperative deep inferior epigastric perforator flap venous congestion with augmentation of venous outflow: flap morbidity and review of the literature. *Plast Reconstr Surg Glob Open* 2013;1:e52.
- 8 Francis A, Baynosa R. Ischaemia-Reperfusion injury and hyperbaric oxygen pathways: a review of cellular mechanisms. *Diving Hyperb Med* 2017;47:110–7.

Copyright 2022 BMJ Publishing Group. All rights reserved. For permission to reuse any of this content visit <https://www.bmj.com/company/products-services/rights-and-licensing/permissions/>  
BMJ Case Report Fellows may re-use this article for personal use and teaching without any further permission.

Become a Fellow of BMJ Case Reports today and you can:

- ▶ Submit as many cases as you like
- ▶ Enjoy fast sympathetic peer review and rapid publication of accepted articles
- ▶ Access all the published articles
- ▶ Re-use any of the published material for personal use and teaching without further permission

**Customer Service**

If you have any further queries about your subscription, please contact our customer services team on +44 (0) 207111 1105 or via email at [support@bmj.com](mailto:support@bmj.com).

Visit [casereports.bmj.com](http://casereports.bmj.com) for more articles like this and to become a Fellow